



# **PALM-COEIN:** **Your AUB** **Counseling** **Guide**

# 10 million+

## Treat the cause, not the symptom

In the U.S, more than 10 million women between the ages of 35 and 49 are affected by AUB<sup>1</sup>

| Diagnosis | Cause                  |
|-----------|------------------------|
|           | <b>Structural</b>      |
| AUB-P     | Polyps                 |
| AUB-A     | Adenomyosis            |
| AUB-L     | Leiomyoma              |
| AUB-M     | Malignancy/Hyperplasia |
|           | <b>Non Structural</b>  |
| AUB-C     | Coagulopathy           |
| AUB-O     | Ovulatory Dysfunction  |
| AUB-E     | Endometrial Disorders  |
| AUB-I     | Iatrogenic             |
| AUB-N     | Not Classified         |



## AUB-P Polyps

### Symptoms

- Menorrhagia
- Infertility
- Post menopausal bleeding<sup>2</sup>

### Medical relevance

- May be asymptomatic and/or may contribute to AUB. Potential for malignancy and/or infertility.

### Some treatment options include:

Medical therapy, NovaSure<sup>®</sup> endometrial ablation, MyoSure<sup>®</sup> tissue removal, curettage<sup>3</sup>

# AUB-P Polyps

## IMAGING AND DIAGNOSIS

### Sonohysterography (SIS)

- Substantial evidence exists to indicate that sonohysterography is superior to transvaginal ultrasonography in the detection of intracavitary lesions, such as polyps and submucosal leiomyomas.<sup>4</sup>
- SIS provides better information on the general size and location of cavitory abnormalities in comparison to TVUS.<sup>5</sup>

### Hysteroscopy

- Hysteroscopy offers direct visualization of the uterine cavity including exact information on specific size and location.
- Hysteroscopy allows the ability to see and treat intracavitary pathology simultaneously.<sup>6</sup>



## AUB-A Adenomyosis

### Symptoms

- AUB
- Dysmenorrhea
- Enlarged uterus<sup>3</sup>

### Medical relevance

- Endometrial tissue within the myometrium. Often found by MRI, the relationship between Adenomyosis and AUB is not well understood.

### Some treatment options include:

NSAIDs, hormone therapy, uterine artery embolization, NovaSure<sup>®</sup> endometrial ablation, hysterectomy<sup>3</sup>

# AUB-A Adenomyosis

## RADIOLOGIC FINDINGS

- Localized thickening of junctional zone
- Poorly defined endometrial borders
- High signal intensity spots MRI/TVUS<sup>1</sup>

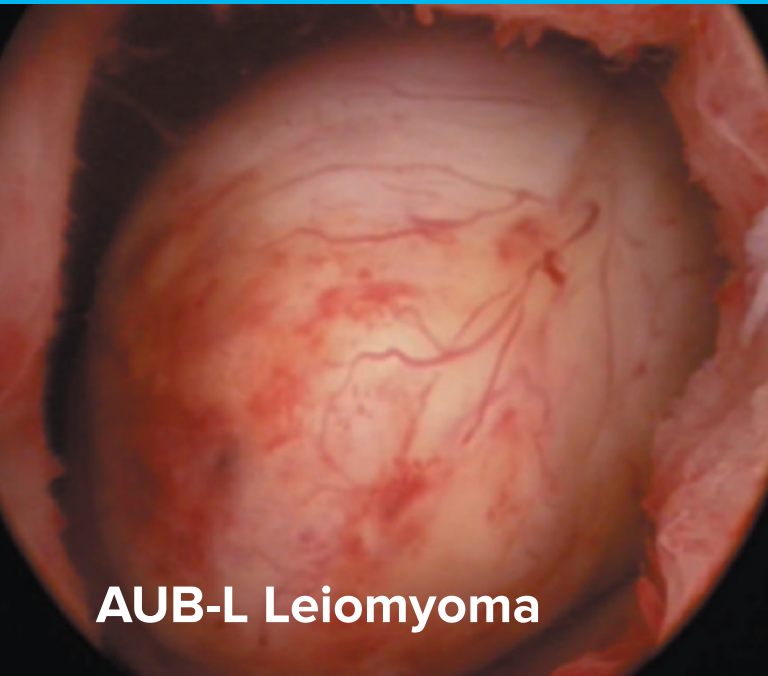
## IMAGING AND DIAGNOSIS

### Transvaginal ultrasound

- Transvaginal ultrasonography may perform less well in the presence of an enlarged uterus or with coexisting myomas.<sup>4</sup>

### MRI

- Some experts recommend transvaginal ultrasonography as the initial screening test for AUB and MRI as a secondline test when the diagnosis is inconclusive, when further delineation would affect patient management, or when coexisting uterine myomas are suspected.<sup>4</sup>



## AUB-L Leiomyoma

### Symptoms

- UB
- Pelvic pressure and/or heaviness
- Urinary frequency
- Dysmenorrhea
- Abdominal enlargement
- Pregnancy loss
- Infertility<sup>7</sup>

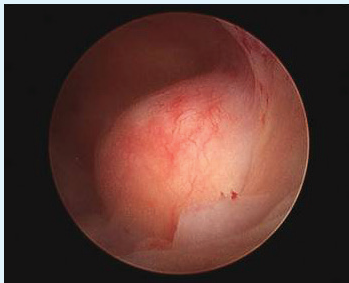
### Risk factors

- Nullparity
- Obesity
- Family history
- Hypertension
- African-American<sup>7</sup>

### Some treatment options include:

Hormone therapy, MyoSure<sup>®</sup> tissue removal, uterine artery embolization, myomectomy, hysterectomy<sup>8</sup>

# AUB-L Leiomyoma



## IMAGING AND DIAGNOSIS

### Transvaginal ultrasound

- The primary imaging test of the uterus for the evaluation of AUB is transvaginal ultrasonography.<sup>4</sup>

### Sonohysterography (SIS)

- If TVUS images are not adequate or further evaluation of the cavity is necessary, then sonohysterography (SIS) or hysteroscopy (preferably in the office setting) is recommended.<sup>6</sup>





# AUB-M Malignancy/Hyperplasia

## Risk factors

- Obesity
- Prolonged anovulation
- Post menopausal estrogen replacement therapy
- Tamoxifen
- Family history
- Hypertension
- Diabetes<sup>s</sup>

## Some treatment options include:

Hormone therapy, radiation therapy, chemotherapy, hysterectomy<sup>s</sup>

# AUB-M

## Malignancy/Hyperplasia

### Diagnostic approach

- Endometrial tissue sampling should be performed in patients with AUB who are older than 45 years as a first-line test.<sup>8</sup>
- Endometrial sampling also should be performed in patients younger than 45 years with a history of unopposed estrogen exposure (such as seen in obesity or PCOS), failed medical management, and persistent AUB.<sup>8</sup>
- Endometrial biopsy has high overall accuracy in diagnosing endometrial cancer when an adequate specimen is obtained and when the endometrial process is global.<sup>8</sup>

# AUB-C Coagulopathy

## INHERITED (Von Willebrand)

### Examples

- Von Willebrand disease (13%)
- Carrier states for factor deficiencies
- Idiopathic thrombocytopenia purpura (platelet # abnormalities)
- Platelet dysfunctions (platelet function abnormalities)
- Leukemia
- Liver dysfunction<sup>9</sup>

### Diagnostic approach

- Initial tests should include a CBC with platelets, prothrombin time, and partial thromboplastin time (fibrinogen or thrombin time are optional).
- Depending on the results of the initial tests, specific tests for von Willebrand disease or other coagulopathies may be indicated.<sup>3</sup>

### Some treatment options include:

Therapeutic environment, gonadal steroid agents, antifibrinolytic therapy, NovaSure<sup>®</sup> endometrial ablation<sup>3</sup>

# AUB-O

## Ovulatory Disorders

**PREVIOUSLY CALLED “DUB” ACQUIRED<sup>3</sup>**

### **Symptoms**

- Irregular bleeding patterns

### **Possible causes**

- Hypothalamic dysfunction (stress)
- Polycystic ovary syndrome (PCOS)
- Eating disorders<sup>3</sup>

### **Diagnostic approach**

- Laboratory testing (pregnancy test, complete blood count, measurement of thyroid-stimulating hormone (TSH) levels and cervical cancer screening). Testing for Chlamydia trachomatis should be considered.<sup>4</sup>

### **Some treatment options include:**

Medical therapy, gonadal steroids, NovaSure<sup>®</sup> endometrial ablation, IUD, hysterectomy<sup>3</sup>

# AUB-E

## Endometrial Disorders

### REQUIRES UNDERSTANDING OF STRUCTURED HISTORY AND EXCLUSION

#### Definition

- Ovulatory cycle with no structural or systematic abnormalities

#### Possible causes

- Impaired vasoconstriction (ratio of  $\text{PGF2}\alpha$ :prostacyclin)
- Enhanced fibrinolysis
- Localized hemostatic disorder

#### Diagnostic approach

- No commercial testing available<sup>9</sup>

#### Some treatment options include:

Medical therapy, gonadal steroids, NovaSure<sup>®</sup> endometrial ablation, IUD, hysterectomy<sup>3</sup>

# AUB-I Iatrogenic

## REQUIRES UNDERSTANDING OF STRUCTURED HISTORY AND EXCLUSION

### Examples

- Warfarin
- Heparin
- IUD
- Oral contraceptive

### Possible causes

- BTB a result of poor patient compliance
- Bleeding induced by gonadal steroidal therapy

### Diagnostic approach

- Targeted medical history<sup>8</sup>

### Some treatment options include:

Estrogen/Progestin contraceptive agents,  
therapeutic agents<sup>3</sup>

# AUB-N Not Classified

## REQUIRES UNDERSTANDING OF STRUCTURED HISTORY AND EXCLUSION

### Examples

- Ateriovenous malformations
- Associations with some systematic diseases
- Endometritis

### Diagnostic approach

- Doppler scanning
- Biopsy and cultures<sup>3,8</sup>

## References

1. "Diagnosis of abnormal uterine bleeding in reproductive-aged women." Practice Bulletin No. 128 197-203. American College of Obstetricians and Gynecologists. *Obstet Gynecol* 2012; 120; 197-206.
2. Salim et al. Diagnosis and Management of Endometrial Polyps: A Critical Review of the Literature. *J Minim Invasive Gynecol.* 2011 Jul 21.
3. Munro MG *Abnormal Uterine Bleeding*. Cambridge, 2010 Cambridge University Press. Chapter 9-11. Pages 89-116.
4. Kelekci S, Kaya E, Alan M, Alan Y, Bilge U, Mollamahmutoglu L. Comparison of transvaginal sonography, saline infusion sonography, and office hysteroscopy in reproductive-aged women with or without abnormal uterine bleeding. *Fertil Steril* 2005;84:682-6. (Level II-3).
5. Schwarzler P, Concin H, Bosch H, Berlinger A, Wohlgenannt K, Collins WP, et al. An evaluation of sonohysterography and diagnostic hysteroscopy for the assessment of intrauterine pathology. *Ultrasound Obstet Gynecol* 1998;11:337- 42. 6.
6. Hysteroscopy. Technology Assessment No. 7. American College of Obstetricians and Gynecologists. *Obstet Gynecol* 2011;117:1486-91.
7. Baird DD, et al. High cumulative incidence of uterine leiomyoma in black and white women: Ultrasound evidence. *American Journal of Obstetrics and Gynecology.* 2003;188:100.
8. Munro MG, Critchley HO, Broder MS, Fraser IS. FIGO classification system (PALM-COEIN) for causes of abnormal uterine bleeding in nongravid women of reproductive age. 204 Practice Bulletin *Abnormal Uterine Bleeding OBSTETRICS & GYNECOLOGY* age. FIGO Working Group on Menstrual Disorders. *Int J Gynaecol Obstet* 2011;113:3-
9. Lukes MD, et al. *Fertility and Sterility* "Disorders of hemostasis and excessive menstrual bleeding: prevalence and clinical impact." 2005 Nov; 14 (5) 1338-1344.

[hologic.com](http://hologic.com) | [info@hologic.com](mailto:info@hologic.com) | +1.781.999.7300